



# Surgical treatment of therapy-resistant reflux after Roux-en-Y gastric bypass. A case series of the modified Nissen fundoplication

Jan Colpaert, Julie Horevoets, Leander Maes, Gilles Uijterhaegen & Bruno Dillemans

To cite this article: Jan Colpaert, Julie Horevoets, Leander Maes, Gilles Uijterhaegen & Bruno Dillemans (2019): Surgical treatment of therapy-resistant reflux after Roux-en-Y gastric bypass. A case series of the modified Nissen fundoplication, Acta Chirurgica Belgica, DOI: [10.1080/00015458.2019.1696028](https://doi.org/10.1080/00015458.2019.1696028)

To link to this article: <https://doi.org/10.1080/00015458.2019.1696028>



Accepted author version posted online: 20 Nov 2019.  
Published online: 29 Nov 2019.



Submit your article to this journal [↗](#)



Article views: 13



View related articles [↗](#)



View Crossmark data [↗](#)

## Surgical treatment of therapy-resistant reflux after Roux-en-Y gastric bypass. A case series of the modified Nissen fundoplication

Jan Colpaert, Julie Horevoets, Leander Maes, Gilles Uijterhaegen and Bruno Dillemans

Department of Surgery, AZ Sint-Jan Brugge, Bruges, Belgium

### ABSTRACT

**Introduction:** Patients with intractable reflux after RYGB have limited treatment options. Here a modified Nissen fundoplication (MNF) as described by N. Kawahara might be the answer.

**Methods:** In this retrospective case study we identified six patients with therapy-resistant GERD after RYGB. All six were treated with a MNF, using the remnant stomach to construct the fundoplication. Short term follow-up 1 month and 6–12 months postoperatively was conducted to inquire about GERD symptoms.

**Results:** Six patients underwent a MNF. Three out of six patients had had a gastric band in their medical history. Upper GI barium swallow test revealed herniation of the gastric pouch in 4/6 patients. After surgery all patients were symptom free and 4/6 completely stopped PPI treatment.

**Discussion:** Mechanisms of new onset or deteriorating GERD after RYGB are herniation of gastric pouch and destruction of the lower esophageal sphincter after banding. Both problems are tackled when constructing a MNF.

**Conclusion:** Complete symptom relief was seen 1 month after MNF. The procedure seems safe, feasible and effective. The study is limited by small sample size and short follow-up yet shows clear improvement of symptoms. Larger trials are needed to establish validity of the MNF.

### ARTICLE HISTORY

Received 12 November 2018  
Accepted 18 November 2019

### KEYWORDS

Gastro-esophageal reflux;  
Roux-en-Y gastric bypass;  
Nissen fundoplication;  
modified Nissen  
fundoplication;  
GERD; obesity

### Introduction

Gastro-esophageal reflux disease (GERD) affects a large portion of morbidly obese patients. An incidence of up to 61% has been cited in the obese population [1]. Large numbers of studies have reported a clear improvement in GERD symptoms after Roux-en-Y gastric bypass (RYGB), making it the gold standard surgical treatment in the morbidly obese patient with GERD [2–4]. The main mechanisms of the antireflux effect of a RYGB are fourfold: a derivation of bile, weight loss which results in decreased abdominal pressures over the lower esophageal sphincter (LES), a lowered acid production in the gastric pouch and rapid pouch emptying. In a review of the Bariatric Outcomes Longitudinal Database, it was clearly demonstrated that GERD score improvement was the highest in the RYGB group, with 56.5% of patients showing amelioration of symptoms [5].

Although RYGB is widely accepted as the stand-alone procedure of choice for GERD treatment in the morbidly obese, it is not a conclusive treatment for all patients [6,7]. Up to 22% of patients who underwent a successful RYGB operation still

complain about postoperative GERD symptoms [6]. The initial treatment for GERD in the post-bariatric patient remains conservative and is similar to that of the general population. Optimal medical therapy combined with lifestyle changes such as weight loss and dietary optimization form the basis for treatment and prevention of this acid reflux. In case of continuing or worsening symptoms despite pharmacotherapy further evaluation is warranted [8]. Useful diagnostic tests such as 24-hour pH study, an upper gastro-intestinal endoscopy, esophageal manometry and Barium swallow X-rays can help further differentiate the problem.

For these patients with persisting GERD after bariatric surgery and despite optimal medical therapy there is no clear consensus on further treatment options. To the best of our knowledge only two surgical case reports have been published on surgical intervention with either a conversion to a Belsey Mark IV fundoplication [9] or a fundoplication using the remnant stomach [10]. Both techniques had excellent short postoperative outcomes. Other techniques using the MUSE system<sup>TM</sup>, Stretta Procedure<sup>TM</sup> and Esophyx<sup>TM</sup> are all

proposed emerging endoluminal therapies or the magnetic Linx device<sup>TM</sup> have no clear available data on their outcomes [8].

Building on these earlier reported cases, we wanted to further evaluate the feasibility and use of a modified Nissen fundoplication (MNF) in gastric bypass patients with therapy resistant gastro-esophageal reflux disease.

## Methods

### *Study design and setting*

We wanted to evaluate the safety and feasibility as well as the impact on GERD of the MNF procedure as described by Kawahara et al. [10]

This retrospective case study was conducted at a secondary referral hospital for bariatric surgery in Bruges, Belgium. From 1 April 2017 over the duration of 1 year, we identified six patients with therapy-resistant gastro-esophageal reflux after bariatric surgery. Inclusion criteria were symptoms of reflux disease despite optimal medical therapy with high-dose proton-pump inhibitors (PPI's) and lifestyle changes in patients who already underwent a gastric bypass.

All six were treated with a MNF, using the remnant stomach to construct the fundoplication. The details of the surgery and the specificities of our approach are mentioned lower in the article. One person underwent a concomitant gastrojejunal sleeve because of weight regain and the finding of a large pouch during surgery. The procedure was performed by an experienced surgeon and his team with a long-standing experience in bariatric and bariatric revisional surgery. Data were collected from patient files. Any incomplete data were retrospectively added through thorough anamnesis on consultation. A short term clinical follow-up 1 month after surgery, either on consultation or telephonically was conducted to inquire about persisting or improving GERD symptoms, as well as a follow-up 6–12 months postoperatively.

### *Rationale of the procedure*

The original Nissen fundoplication was first performed by Dr. Rudolph Nissen in 1955. He published the results of two cases in an edition of the 1956 Swiss Medical Weekly [11]. In 1961, he published a more detailed overview of the procedure [12]. The main mechanism of the fundoplication is based on reinforcing the closing function of the lower esophageal sphincter (LES). The esophageal

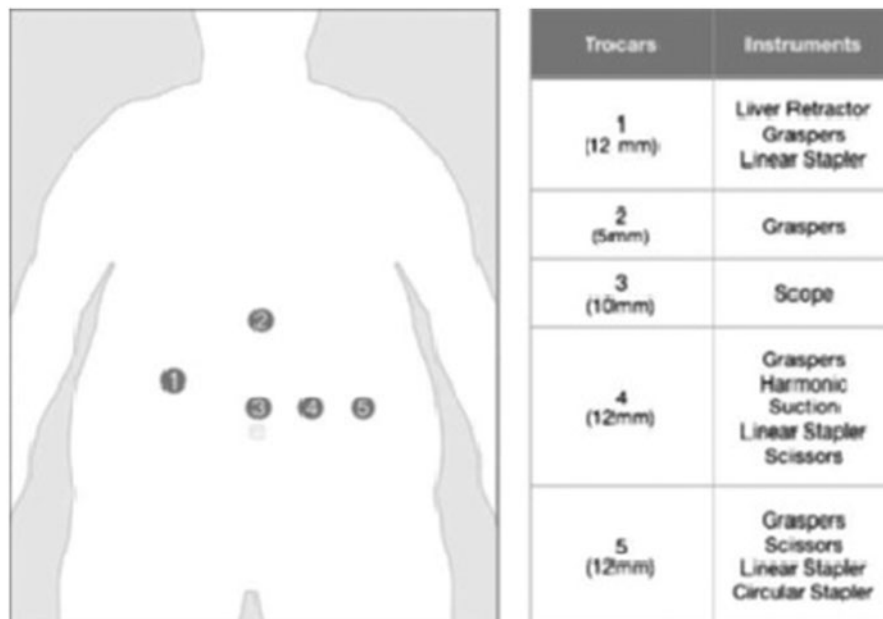
hiatus is also narrowed down by sutures to prevent or treat concurrent hiatal hernia.

The rationale behind the MNF after RYGB lies in the fact that -by wrapping the remnant stomach around the gastro-esophageal junction – the LES is sufficiently reinforced. Secondly, by reducing any intrathoracic herniation when necessary and by closing of the pillars any further herniation is prevented. Thus both main mechanisms of gastro-esophageal reflux are tackled in one surgery. A third possible explanation for the improvement of GERD after hiatoplasty and Nissen fundoplication may be found in the maintenance of a segment of intra-abdominal esophagus.

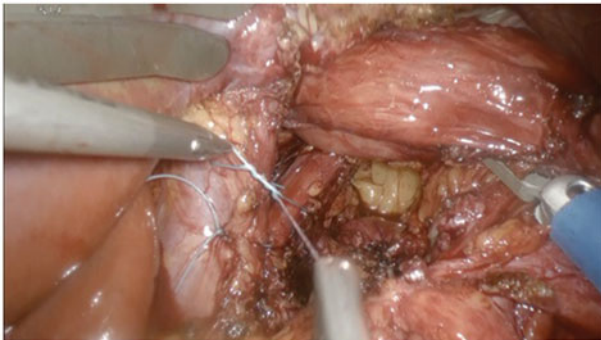### *Procedure*

In essence, a laparoscopic 360° fundoplication was performed to reinforce the LES by wrapping the excluded stomach around the distal esophagus. The patient was put in beach chair position and a pneumoperitoneum of 15 mmHg was established. One scope trocar and four utility trocars were placed, using the same position as the initial gastric bypass surgery (Figure 1) [13]. After initial adhesiolysis from the previous surgery the excluded stomach is carefully isolated by dividing the short gastric vessels with harmonic scissors. Subsequently the lesser omentum (or hepatogastric ligament) is opened at the pars flaccida and dissection continues toward the diaphragm to expose the right crus. Further blunt dissection is used to separate the right crus from the esophagus. The dissection is then continued to free the esophagus circumferentially.

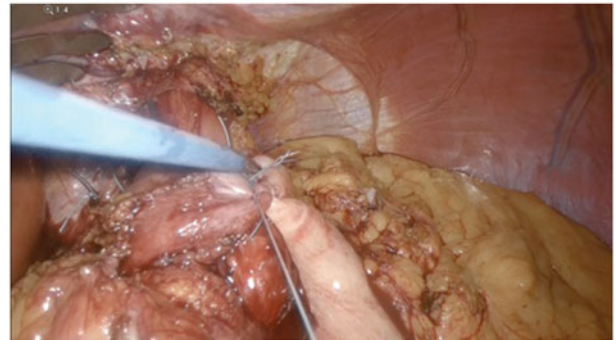
Once the hiatus is meticulously dissected the crurae are approximated with interrupted stitches inferior to the esophagus. The crucial part here is to prevent a kinking of the esophagus which might happen when the crurae are approximated too tightly. Consecutively a loose wrap of approximately 3 cm is constructed around the esophagus using the remnant stomach with an intra-esophageal 32-Fr bougie for guidance. The mobilized remnant stomach is pulled behind the gastric pouch and the anterior and posterior lips are sutured together using three interrupted stitches. The middle stitch is also used to fix the wrap to the esophagus anteriorly. (Figures 2–4) All stitches were placed using the EndoStitch device with Ethibond 2/0 sutures. Finally, the smooth passage is checked by sliding the 32-Fr bougie back and forth through the wrap. After careful hemostasis and methylene blue leak



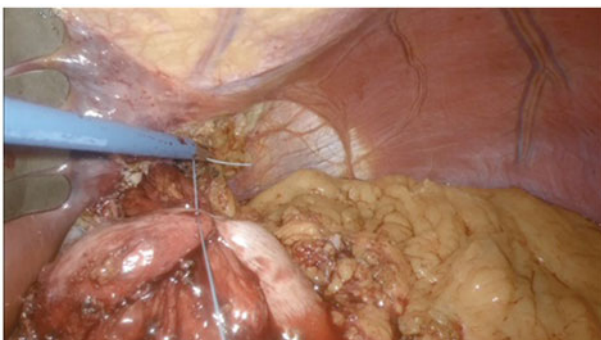
**Figure 1.** Position of the trocars as described by Dillemans et al. [15].



**Figure 2.** Cruraplasty using EndoStitch. The crucial part of this step is to prevent kinking of the esophagus.



**Figure 4.** Completing the loose 3 cm wrap with three interrupted stitches.



**Figure 3.** Creating a loose wrap with the remnant stomach around the distal esophagus.

test the surgery is completed. In one case, because of associated weight regain, the dilated gastric pouch was resized before performing the modified Nissen fundoplication.

## Results

Over the course of 1 year, six patients received this specific surgical treatment. Of these six patients,

two were male and four female. Age of the patients at the time of their MNF ranged from 20 to 60 years old with a mean age of 42.

Each patient had already undergone a laparoscopic RYGB. Five of these were performed in our center, one RYGB was performed elsewhere. All patients had severe to morbid obesity before their initial RYGB. Body Mass Index (BMI) before the RYGB ranged from 35.1 to 58.9 with a mean BMI of 42.5. All patients had known a satisfactory initial weight loss with BMI's between 19 and 31 (mean 24.2).

Two patients had already undergone adjustable gastric banding before RYGB. In both cases, the band had been removed due to associated problems (slipping, reflux and dysphagia). One patient had his band removed before the RYGB, the other patient had the band removed simultaneously with the RYGB surgery. A third patient underwent gastric banding for weight regain after his initial RYGB surgery.

Timing between RYGB and MNF varied from 3 to 11 years. During this interval, two patients



underwent surgery for an internal herniation and one patient had a revisional bariatric procedure for weight regain with adjustable banding of the pouch. This band was later removed during the MNF. At the time of the MNF, mean BMI was 31.3 (range 24.7–40.5). This is in line with the increase in weight as often seen over the years after bariatric surgery.

Before the initial RYGB, four out of six patients already had GERD symptoms and acid reflux. This corresponds with the 61% incidence of reflux in the obese population as found in the literature [1]. After RYGB, all patients were asymptomatic for at least 1 year. We found a gradual increase in GERD-related complaints and symptoms starting as soon as 1 year after RYGB.

Main complaints before the MNF were GERD-related. Heartburn and regurgitation were found in 6 out of 6 patients. Four out of six patients also manifested a gradual weight regain. One patient experienced intermittent episodes of postprandial vomiting. Associated comorbidities were mainly obesity-related with dyspnea on exertion, orthopaedic and psychological discomfort. Prior to surgery all patients were put on high dose PPI's<sup>1</sup> yet remained symptomatic. Upper GI series with barium swallow revealed herniation of the pouch and a delayed passage of contrast in 4 out of 6 patients. Further investigation with gastroscopy showed a grade A esophagitis in 2 out of 6 patients. One patient had esophagitis grade C and two others had a sliding hernia on gastroscopy. One patient with a normal gastroscopy underwent further investigations with pH-manometry which showed some regurgitation but no significant acid exposition of the lower esophagus (pH > 4). Even though not all patients had objectified esophagitis, they demonstrated clear symptoms of GERD, impacting their quality of life. The absence of any esophagitis on gastroscopy – despite obvious symptoms – might be attributed to the long-term PPI use masking clear signs of GERD.

One month after surgery, 4 out of 6 patients could already permanently stop their PPI's and were completely symptom free. One patient was still on low dose PPI's because of esophagitis grade A on control gastroscopy. Before his MNF, however, the gastroscopy had shown a grade C reflux esophagitis. Subjectively he no longer experienced any GERD-related symptoms and was very satisfied with the surgery. Another patient was still using PPI's 1 month after surgery but stated to be completely symptom free and very content. Seeing

the good symptomatic results of this surgery no follow-up gastroscopy was performed in this group.

In further follow-up 6 months to 1 year postoperatively, we find that 3 out of 6 patients (50%) still had adequate symptom relief with no need for PPI's. The remaining three however had started taking low-dose PPI's<sup>2</sup> again due to recurrence of the reflux symptoms (heartburn, dyspepsia and/or regurgitation) although they all stated to be much more comfortable now than before their surgery.

As an additional benefit, we found a marked weight loss postoperatively. Both with or without gastrojejunal sleeve for dilated pouch the general tendency was that of a loss of around 1.8 points of BMI. One patient however had weight regain after the MNF due to an orthopedic trauma and long-term immobilization which severely reduced his physical activity level.

After 6- to 12-month follow-up, we did see a significant increase in weight regain. Two out of six patients had returned to their initial weight from before the RYGB. Four out of six patients still remained stable with a weight similar to that 1 month after the MNF.

Both in the 1 month and in the 6- to 12-month postoperative follow-up no complications were identified.

## Discussion

Six patients with a RYGB and intractable acid reflux despite optimal medical therapy underwent a laparoscopic MNF in our center. The first two cases were performed in April of 2017. Strengthened by the positive results of these first cases four more patients were operated for the same problem using the same technique. To the best of our knowledge the only time this surgery has previously been described was in a case report by N. Kawahara [10].

Although the RYGB remains the gold standard treatment for GERD in the obese, it does not always offer a permanent solution [6,7]. Up to 22% of patients who underwent a successful RYGB operation still complain about postoperative GERD-related symptoms [6]. In our series we find that a large portion of the reflux symptoms after RYGB are associated with earlier or concomitant gastric banding or supradiaphragmatic herniation of the gastric pouch. Gastric banding either before or after the bypass-operation has a detrimental effect on the LES which can contribute to

worsening of GERD [14]. In four out of six patients there was a herniation of the pouch on upper GI series. The altered pressure systems when the gastric pouch herniates into the thoracic cavity also contributes to a reduced functioning of the LES and more gastro-esophageal reflux.

The initial resolution of symptoms 1 month after surgery is a strong indicator of good results but can be biased by the fact that all patients also lost weight, which in turn has an impact on symptom reduction. One patient also underwent a gastrojejunum sleeve together with the MNF, this resulted in a more pronounced weight loss and also lowers acid production which might further positively affect symptoms of GERD. Six months to 1 year after surgery however we see an increase in overall weight in three out of six patients with still sufficient symptom control. This finding suggests that the initial weight loss is not the main reason for symptom relief. Other confounding factors such as a short term placebo effect postoperatively and the removal of the band in one case might also have impact symptom relief.

Some might argue that the mechanism of a MNF loses part of its function as the remnant stomach does not fill with food or gas, thus giving less pressure around the esophagus. We however hypothesized that the wrapping of the stomach around the pouch gives enough a mechanical barrier to strengthen the LES and prevent reflux. This mechanism of a mechanical barrier was also used in the Angelchik prosthesis from the late 1970s and early 80s [15]. The C-shaped ring with Dacron fitted tape created a mechanical barrier with good initial results on GERD symptoms but was abandoned after long-term complications such as slipping and erosion became obvious [16].

Despite some promising results in our first six patients this study has some severe limitations. The biggest limitation of this study is its relatively small sample size and the lack of strong objective data to evaluate the efficacy. In order to establish a more definitive answer to whether or not this surgery benefits patients a larger study population is needed. Furthermore, routine barium swallow and pH manometry could be useful to objectively evaluate the functionality of the MNF. Finally, a retrospective case series scores relatively low in the hierarchy of evidence, although being the most prevalent type of clinical research. Nevertheless it can be useful to use a case series to generate hypothesis that are to be tested in larger, randomized trials. Another limitation is the

short follow-up period, however even in this short time period we find a manifest improvement of symptoms.

## Conclusion

This study was mainly used to evaluate the feasibility of a MNF after RYGB. Overall the MNF for therapy-resistant reflux after RYGB seems to have, to some extent, a positive effect up to 1 year postoperatively. Both a complete remission of GERD symptoms in all patients and – as an additional benefit – a marked overall weight loss are seen already 1 month after the revisional surgery. In the 6- to 12-month follow-up, we find a recurrence of symptoms in 50% of patients. These symptoms are currently treated with low-dose PPI's again. Despite this recurrence all six patients attest to a subjective decrease of symptoms and concomitant increase in their quality of life after the MNF.

No postoperative complications were seen. In the hands of a skilled surgeon with experience in revisional bariatric surgery this procedure seems to be safe and feasible. At this point no firm conclusion can be drawn however about the impact on GERD, although we do see a positive tendency in symptom relief.

Further investigation with objective data collection both pre- and postoperatively is needed to corroborate our thesis that the MNF does in fact alleviates intractable acid reflux after RYGB.

## Notes

1. At least one PPI 2 times 40mg daily, whether or not associated with antacids.
2. Low-dose PPI's = 20 to 40 mg omeprazole or pantoprazole daily

## Disclosure statement

None of the authors have any conflict of interest to declare.

## ORCID

Bruno Dillemans  <http://orcid.org/0000-0001-8135-4844>

## References

- [1] Iovino P, Angrisani L, Galloro G, et al. Proximal stomach function in obesity with normal or abnormal oesophageal acid exposure. *Neurogastroenterol Motil.* 2006;18(6):425–432.
- [2] Nelson LG, Gonzalez R, Haines K, et al. Amelioration of gastroesophageal reflux symptoms following

- Roux-en-Y gastric bypass for clinically significant obesity. *Am Surg.* 2005;71(11):950–953. discussion 3–4.
- [3] Mejia-Rivas MA, Herrera-Lopez A, Hernandez-Calleros J, et al. Gastroesophageal reflux disease in morbid obesity: the effect of Roux-en-Y gastric bypass. *Obes Surg.* 2008;18(10):1217–1224.
  - [4] Merrouche M, Sabate JM, Jouet P, et al. Gastroesophageal reflux and esophageal motility disorders in morbidly obese patients before and after bariatric surgery. *Obes Surg.* 2007;17(7):894–900.
  - [5] Pallati PK, Shaligram A, Shostrom VK, et al. Improvement in gastroesophageal reflux disease symptoms after various bariatric procedures: review of the Bariatric Outcomes Longitudinal Database. *Surg Obes Relat Dis.* 2014;10(3):502–507.
  - [6] Frezza EE, Ikramuddin S, Gourash W, et al. Symptomatic improvement in gastroesophageal reflux disease (GERD) following laparoscopic Roux-en-Y gastric bypass. *Surg Endosc.* 2002;16(7):1027–1031.
  - [7] Varban OA, Hawasli AA, Carlin AM, et al. Variation in utilization of acid-reducing medication at 1 year following bariatric surgery: results from the Michigan Bariatric Surgery Collaborative. *Surg Obes Relat Dis.* 2015;11(1):222–228.
  - [8] Altieri MS, Pryor AD. Gastroesophageal reflux disease after bariatric procedures. *Surg Clin North Am.* 2015; 95(3):579–591.
  - [9] Chen RH, Lautz D, Gilbert RJ, et al. Antireflux operation for gastroesophageal reflux after Roux-en-y gastric bypass for obesity. *Ann Thorac Surg.* 2005; 80(5):1938–1940.
  - [10] Kawahara NT, Alster C, Maluf-Filho F, et al. Modified Nissen fundoplication: laparoscopic antireflux surgery after Roux-en-Y gastric bypass for obesity. *Clinics (Sao Paulo).* 2012;67(5):531–533.
  - [11] Nissen R. [A simple operation for control of reflux esophagitis]. *Schweiz Med Wochenschr.* 1956; 86(Suppl 20):590–592.
  - [12] Nissen R. Gastropexy and “fundoplication” in surgical treatment of hiatal hernia. *Digest Dis Sci.* 1961;6(10): 954–961.
  - [13] Dillemans B, Sakran N, Van Cauwenberge S, et al. Standardization of the fully stapled laparoscopic Roux-en-Y gastric bypass for obesity reduces early immediate postoperative morbidity and mortality: a single center study on 2606 patients. *Obes Surg.* 2009;19(10):1355–1364.
  - [14] Khan A, Kim A, Sanossian C, et al. Impact of obesity treatment on gastroesophageal reflux disease. *World J Gastroenterol.* 2016;22(4):1627–1638.
  - [15] Angelchik JP, Cohen R. A new surgical procedure for the treatment of gastroesophageal reflux and hiatal hernia. *Surg Gynecol Obstet.* 1979;148(2): 246–248.
  - [16] Crookes PF, DeMeester TR. The Angelchik prosthesis: what have we learned in fifteen years? *Ann Thorac Surg.* 1994;57(6):1385–1386.