



Laparoscopic Roux-en-Y Gastric Bypass: The Standardized Technique

24

Bruno Dillemans, Bert Deylgat, and Sofie Viskens

Contents

24.1	Introduction	338
24.2	Preoperative Assessment	339
24.2.1	Nutritional Evaluation	339
24.2.2	Medical Evaluation	339
24.2.3	Psychological Evaluation	339
24.3	Operative Technique	339
24.3.1	Material List	339
24.3.2	Patient Positioning and Trocar Placement	339
24.3.3	Creation of the Gastric Pouch	340
24.3.4	Creation of the Gastrojejunostomy	341
24.3.5	Creation of the Jejun-jejunostomy	343
24.3.6	Testing of the Gastrojejunostomy	343
24.3.7	Closure of Petersen's Space and Mesenteric Gap During Entero- enterostomy	343
24.3.8	Completion	345
24.4	Advice for the Initial Cases	345
24.5	Postoperative Care	345
24.6	Conclusion	346

Supplementary Information: The online version contains supplementary material available at [https://doi.org/10.1007/978-3-030-60596-4_22].

B. Dillemans (✉) · S. Viskens
Department of General, Pediatric and Vascular Surgery,
AZ Sint-Jan Brugge–Oostende AV, Bruges, Belgium
e-mail: bruno.dillemans@azsintjan.be;
sofie.viskens@azsintjan.be

B. Deylgat
Department of General Surgery, AZ West, Veurne,
Belgium
e-mail: bert.deylgat@azwest.be

24.7 Key Learning Points 346

References 346

Abstract

In this chapter, the standardized laparoscopic Roux-en-Y gastric bypass is described. The entire procedure is explained in detail, beginning with the patient preparation until the normal postoperative course and follow up. Key steps of the procedure are illustrated with photographs. Possible pitfalls and points of interest are discussed.

Keywords

Standardized Laparoscopic Roux-en-Y gastric bypass · Bariatric surgery · Roux-en-Y gastric bypass: LRYGB: Standardization: Obesity

24.1 Introduction

In 2004, the laparoscopic Roux-en-Y gastric bypass (LRYGB) was added to the list of services. Due to the increasing number of bariatric surgery patients (Fig. 1) at the hospital, a fast, reproducible, and safe procedure, which was easy to teach

the residents and those pursuing fellowship, was needed. Therefore, a fully standardized technique was developed. In 2009 data of 2,606 patients, who underwent the completely standardized LRYGP, were reported with minimal morbidity and mortality. Thus, it proved that the technique was feasible [1], and in 2011, one of the fellows used this technique at a second hospital with good perioperative outcomes, thereby, confirming the reproducibility of this technique [2]. The surgical technique improved ever since, and the stapled closure of the mesenteric gaps was introduced additionally. From the introduction in 2004 to December 2020, 14,800 patients underwent a laparoscopic Roux-en-Y gastric bypass. Furthermore from 2014 406 patients had a laparoscopic banded bypass. Given the increasing demand for revisional bariatric surgery, the same technical standardization was used in these surgeries. The compared outcomes of the vertical banded gastroplasty to gastric bypass in 153 and 329 patients were reported in 2013 and 2019 [3–5]. The experience of conversion of gastric banding to LRYGP in 885 patients was published

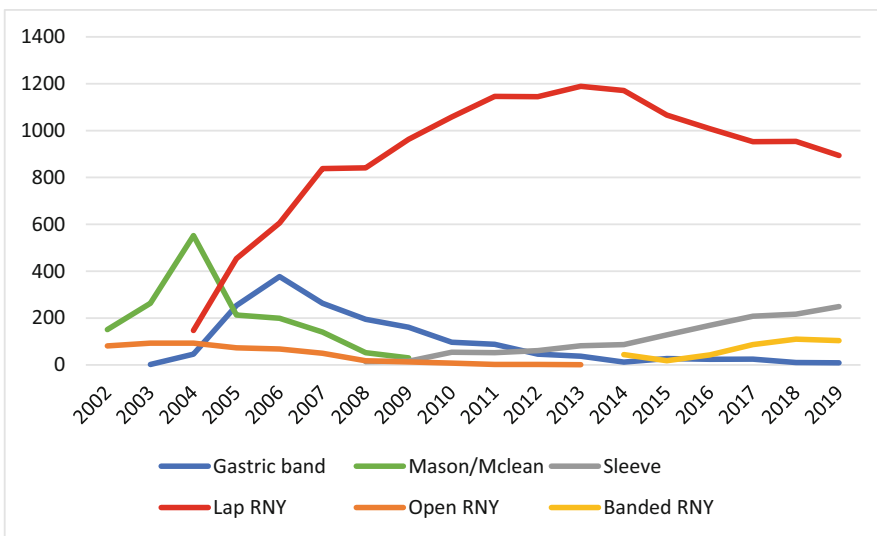


Fig. 1 Frequency of different bariatric procedures between 2002 and 2019 at the center

in 2016 [6]. Converting a gastric banding to LRYGB can be performed with a very low morbidity and zero-mortality in a high-volume revisional bariatric center. With increasing experience and full standardization, the vast majority of conversions after laparoscopic gastric banding can be performed as a single-stage procedure.

24.2 Preoperative Assessment

24.2.1 Nutritional Evaluation

This has been dealt with in detail in ► [Chap. 12, “Preoperative Dietary Evaluation Prior to Bariatric Surgery.”](#)

24.2.2 Medical Evaluation

Please refer to ► [Chap. 11, “Preoperative Medical Evaluation of the Bariatric Surgery Patient,”](#) for details.

24.2.3 Psychological Evaluation

► [Chapter 13, “Psychological Assessment of the Bariatric Surgery Patient,”](#) covers this topic in detail.

24.3 Operative Technique

24.3.1 Material List


- Knife with no 11 blade
- Veress needle (Covidien, USA)
- Trocars: 1 × 5 mm, 3 × 12 mm, 1 × 10 mm
- Insufflation tubing
- Suction device
- Orogastric tube: 34 French Calibration Tube (Bariatric Solutions, Switzerland) or 36 French MID-tube (Mid, France)
- 30° laparoscope
- Light cable
- Ultrasonic dissecting device Harmonic Ace^R laparoscopic shears (Ethicon, USA) or SonicisionTM (Covidien, USA)

- Three laparoscopic clamps (Conmed, USA)
- One Babcock (Conmed, USA)
- 10 mm fan liver retractor (Storz, DEU)
- Laparoscopic needle holder (Ethicon, USA)
- Echelon flexTM 60 mm blue (3.5 mm): 3 cartridges; white (2.5 mm): 3 cartridges (Ethicon, USA) or Endo GIATM 60 mm purple (3–4 mm): 3 cartridges; 45 mm tan (2–3 mm) 1 cartridge, 60 mm tan 2 cartridges (Covidien, USA)
- DST SERIESTM circular EEATM stapler 25 mm blue (3.5 mm) (Covidien, USA) or Endoscopic Curved Intraluminal Stapler ILS 25 mm (Ethicon, USA)
- Two towel clamps
- One polydioxanone suture (PDS) 3/0 cut at 22 cm (Ethicon, USA)
- Two PDS 4/0 cut at 15 cm (Ethicon, USA)
- Multifire Endo HerniaTM (Covidien, USA) or V-lockTM Non-absorbable 15 cm (Covidien, USA)
- StratafixTM 3/0 (Ethicon, USA)
- Endo CloseTM (Covidien, USA)
- One Polysorb 1 suture (Covidien, USA)
- Easyflow drain (Dispomedica, Germany)

24.3.2 Patient Positioning and Trocar Placement

After induction and intubation, a 34/36-French orogastric tube is placed and all patients receive a dose of prophylactic antibiotic (cefazoline). The patient is placed in a 30° reverse Trendelenburg beach-chair position with split-legs. This position not only allows optimal access to the upper part of the abdomen but also increases the abdominal workspace [7]. After disinfection, and draping of the patient, the surgeon stands between the patient’s legs. The first assistant, holding the camera stands on the surgeon’s left and the second assistant on the surgeon’s right, with the video monitor placed at the level of the patient’s head. After installation of insufflation, suction, camera, and an ultrasonic device, a horizontal 1.5-cm incision is made approximately 7.5 cm below the xiphoid. Abdominal insufflation with carbon dioxide (CO₂) begins after insertion of the Veress needle. Intra-abdominal pressures are set at

Fig. 2 Schematic overview of trocar positioning, trocar sizes and overview of the different instruments used by each trocar



Trocars	Instruments
1 (12 mm)	Liver retractor, Graspers, Linear stapler
2 (5 mm)	Graspers
3 (10 mm)	Scope
4 (12 mm)	Graspers, Ultrasonic device, Suction, Linear stapler, Scissors
5 (12 mm)	Graspers, Scissors, Circular stapler

15 mmHg and changed if necessary (increased or decreased), based on workspace. After introduction of a 10-mm scope trocar, the 30° angled scope is introduced, and four additional working trocars are placed under direct vision: a 5-mm port high in the epigastric area in the midline, a 12-mm port in the right upper quadrant, and two 12-mm ports in the left upper quadrant. The latter two ports are placed in the same line as the 10-mm port, while the former 12 mm port is placed higher (subcostal) (Fig. 2). Once the insertion of trocars is completed, the abdomen is inspected for abnormalities and the procedure begins with the creation of the gastric pouch.

24.3.3 Creation of the Gastric Pouch

The 34/36-French stomach tube that is introduced for evacuating any intragastric air is retracted into the esophagus. A Babcock forceps is inserted via the left lateral trocar and exerts traction on the lesser curvature at the level of the antrum. The lesser sac is accessed 4–5 cm below the gastro-esophageal junction by creating a small window in the lesser omentum (Fig. 3a) using a grasper and the ultrasonic device. Introduction of the linear stapler occurs through this window, articulate the stapler to access the lesser curvature perpendicular. The stomach is horizontally cut over 60 mm (Fig. 3b), taking care not to completely transect the stomach. Usually, a blue/purple cartridge is used, but cartridges with higher stapler height are employed when deemed necessary,

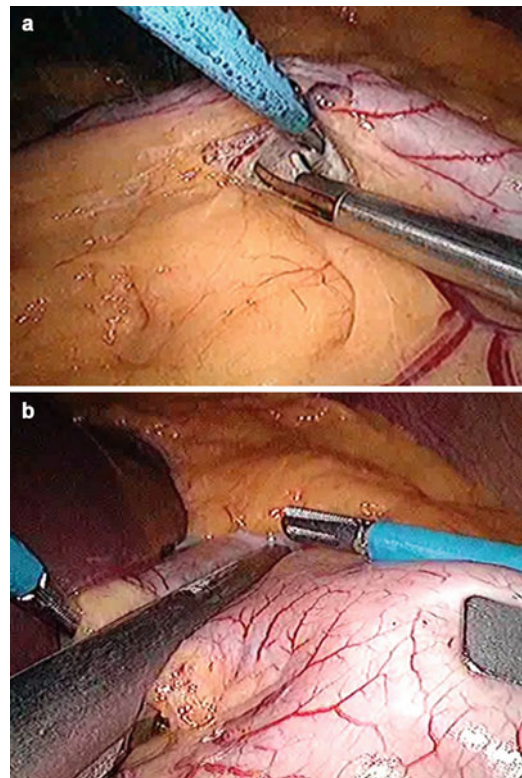


Fig. 3 Creation of the gastric pouch. (a) Start of the dissection at the lesser curvature 5–6 cm below the gastro-esophageal junction. (b) The first linear stapler cuts the stomach horizontally

based on tissue thickness. Posterior gastric adhesions are divided. A second linear 60 mm stapler is introduced through the left medial trocar and positioned toward the angle of His starting from the most lateral point of the horizontal transection

line. Guided by the 34-French orogastric tube, the stapler is closed and fired making sure not to leave a posterior sac (Fig. 4a). The next step consists of dissecting the angle of His. Anteriorly, the dissection extends as deep as possible by using the ultrasonic device as a dissector, while applying traction at the fundus with the Babcock (Fig. 4b). Posteriorly, the window is opened just lateral to the left crus by blunt dissection, using the Babcock and the inserted gastric tube for traction. Finally, the pouch is created by vertically firing

one or two 60 mm cartridges in the direction of and through the created window, along the gastric tube (Fig. 4c). Upon completion, the orogastric tube is pulled back into the esophagus.

In patients with BMI > 45 kg/m² and age <50 years putting a non-adjustable band on top 2 cm above the gastro-jejunal anastomosis to reinforce the persistent weight loss, can be considered [8]. In patients BMI > 45 kg/m² and age >50 years the malabsorptive effect can be enhanced (x.3.4 refers to [Creation of the Gastrojejunostomy](#)).

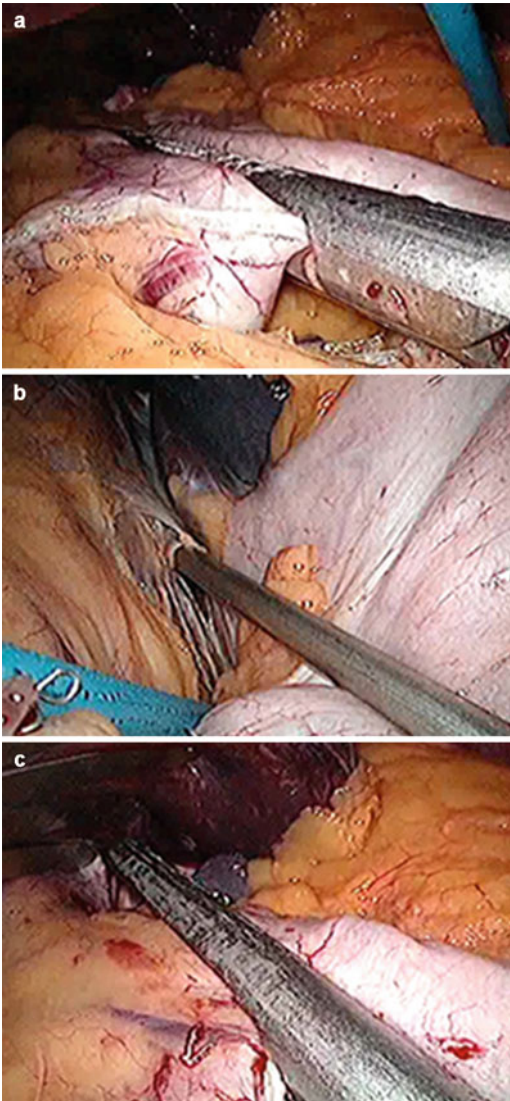


Fig. 4 (a) Vertical transection of the stomach along a 34-French orogastric tube. (b) Opening of the angle of His, (c) Final stapling at the angle of His

24.3.4 Creation of the Gastrojejunostomy

A small portion of the lower left corner of the pouch is excised using the ultrasonic device (Fig. 5a). The opening is stretched and a 3/0 PDS purse-string suture is sewn in (Fig. 5b). After extending the left lateral port site incision

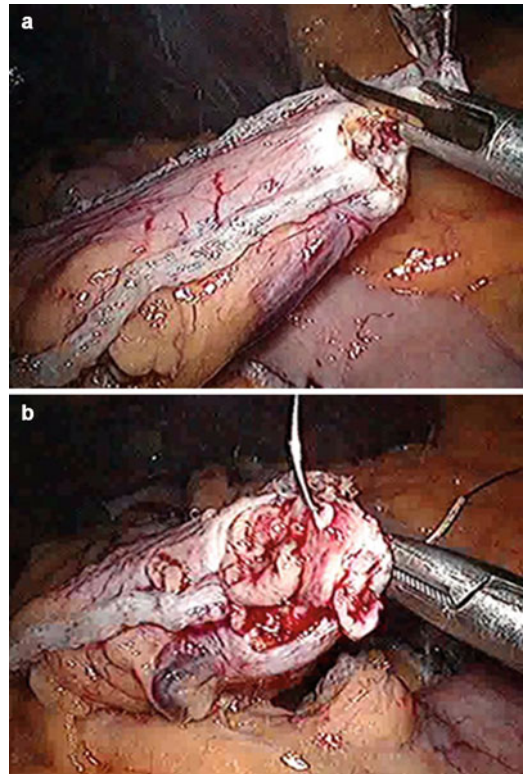


Fig. 5 Creation of the gastrojejunostomy. (a) Opening of the gastric pouch in the lower left corner. (b) Purse-string suturing with PDS 3/0

up to 2.5 cm, the interior opening in the abdominal wall is bluntly dilated with a scissor and two fingers. A blue 25-mm DST Series™ circular EEA™ stapler/ Endoscopic Curved Intraluminal Stapler ILS 25 mm is then introduced intra-abdominally. To prevent losing abdominal pressure, the skin is closed tight around the stapler using a towel clamp. The anvil is introduced into the gastric pouch opening (Fig. 6). The pouch construction is completed by closing the purse-string around the anvil. A final inspection is performed to ensure that the tissue is tight around the anvil, excess mucosa and fat are removed, and veins or arteries running toward the future anastomotic site are excised to prevent bleeding. Thereafter, the greater omentum is lifted and the transverse colon is visualized. The omentum is split longitudinally on the left side of the midline (Fig. 7a). Next, the ligament of Treitz is located (Fig. 7b). Using the ligament, the inferior mesenteric vein, and the root of the transverse mesocolon with the mesentery as landmark, the loop of jejunum is stretched up from this point in an anti-clockwise and antecolic direction to the gastric pouch. The length of the biliary limb can be maximally 100 cm, depending on the degree of tension on the gastroenterostomy. Based on experience, the mesentery becomes shorter if one extends beyond this point. If a sufficient length cannot be obtained, a retrocolic-retrogastric pull-up must be performed.

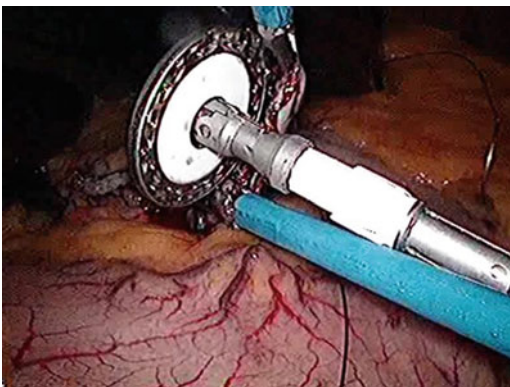


Fig. 6 Introduction of the anvil of the circular stapler and tying of the purse string

If the patient has BMI > 45 kg/m² and age > 50 years, consider enhancing the malabsorptive effect by lengthening the biliary limb (long limb bypass). In these cases, the alimentary limb is shortened to 75 cm [9].

An enterotomy is created 5–10 cm proximal to the designated anastomotic point, and the circular stapler is introduced into the jejunal loop in a distal direction (Fig. 8a). The jejunum is prone to perforations with even a slight traction with the spike; hence, it is necessary to exercise caution in order to avoid perforations in the bowel wall, in an anti-mesenteric direction. Next, the stapler is connected to the anvil (Fig. 8b) and the anastomosis is completed by closing and firing the stapler. The superfluous 5–10 cm long small bowel segment, remaining from the previously created opening, is then transected 1 cm proximal to the gastrojejunostomy using a linear stapler with a 60-mm white/tan cartridge, thus, avoiding a long blind loop of jejunum (Fig. 9).

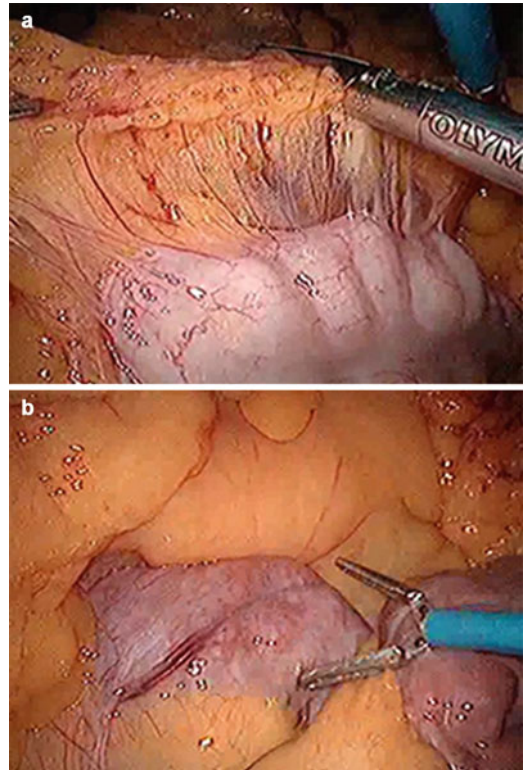


Fig. 7 (a) Division of the greater omentum, (b) Identification of the ligament of Treitz

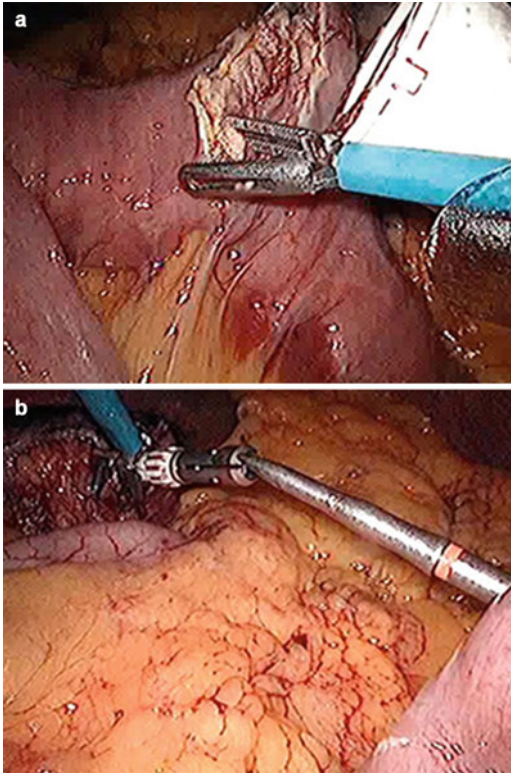


Fig. 8 (a) Enterotomy 30–100 cm from the angle of Treitz. (b) Antimesenteric perforation of the jejunum with the spike after introduction of the circular stapler

24.3.5 Creation of the Jejunojejunostomy

An alimentary limb of 130 cm (or shorter (e.g., 75 cm) when the biliary limb is lengthened) is marked, and an anti-mesenteric opening is created in the jejunum (Fig. 10a). A clamp, introduced in the left lateral trocar site, is placed just distal to this opening as a reference point. Similarly, the biliopancreatic limb is accessed at a distance of 10 cm proximal to the enterotomy (Fig. 10b). A linear 60/45 mm stapler with a white/tan cartridge is introduced via the right trocar, first, in the biliopancreatic limb and then, in the alimentary limb by aiming toward the pelvis (Fig. 10c). After positioning the stapler in the small bowel, the stapler is brought up in the direction of the costal margin and opened again, while holding the small bowel in place, before firing. This maneuver makes sure that the side-to-side anastomosis is

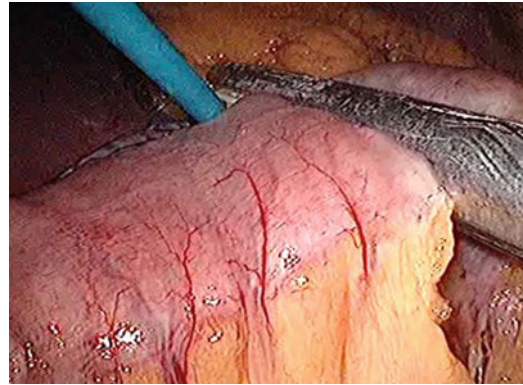


Fig. 9 Finalization of the anastomosis by transection of the remaining small bowel 1 cm proximal to the gastrojejunostomy

anti-mesenteric. The resulting enterotomy defect is closed by a running suture transversely (to prevent stenosis) of barbed resorbable 3.0 Stratafix (Fig. 11a). In the final step, the remaining blind loop of the biliopancreatic limb is transected with a linear stapler through the right trocar (Fig. 11b). Afterwards, this resected piece of bowel is removed via the left lateral trocar.

24.3.6 Testing of the Gastrojejunostomy

After positioning of the orogastric tube at the level of the gastrojejunostomy, leakage is checked by forcefully injecting 60 mL of methylene blue and air while closing the alimentary limb distally. If any leakage is present or if some traction is detected, the gastrojejunostomy is reinforced with some additional stitches of an absorbable monofilament suture (Fig. 12).

24.3.7 Closure of Petersen's Space and Mesenteric Gap During Entero-enterostomy

Although the antecolic-antegastric technique has the lowest incidence of internal hernias, and closure of the defects have their own advantages and disadvantages [10–12]; to prevent internal hernias the mesenteric gabs are closed using a stapler or

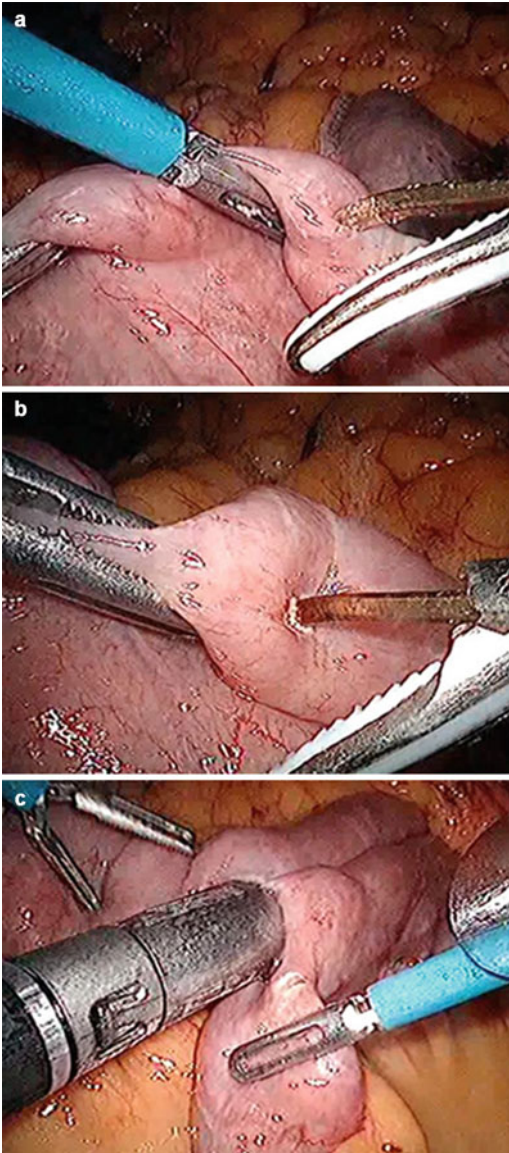


Fig. 10 Creation of the jejunostomy. (a) Anti-mesenteric opening in the alimentary limb. (b) Anti-mesenteric opening in the biliopancreatic limb. (c) Side-to-side anastomosis with a linear 60-mm stapler

V-lock. The mesenteric gap is closed starting from the blind loop downwards, while keeping the alimentary limb aside (Fig. 13a). It is advisable to exercise caution, by avoiding a closure of the gap too close to the mesentery of the alimentary limb, because of the risk of bleeding and tension at the gastroenterostomy site. Pushing up the transverse colon with the Babcock from the left lateral trocar

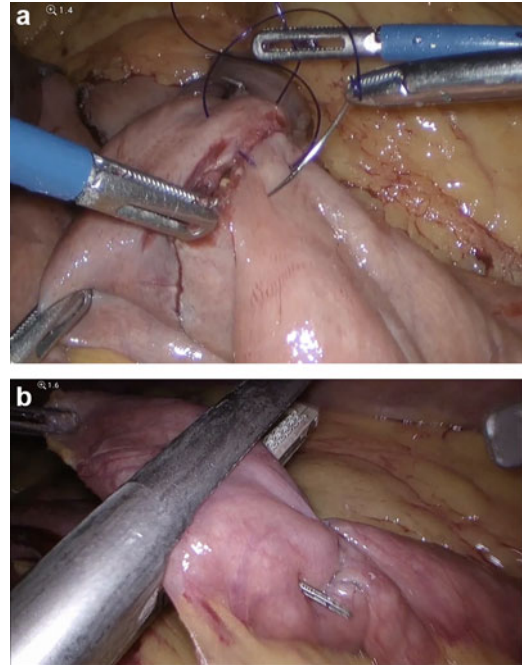


Fig. 11 Creation of the jejunostomy. (a) Closure of the enterotomy defect using running suture stratafix 3.0. (b) Transection of the remaining blind loop of the biliopancreatic limb

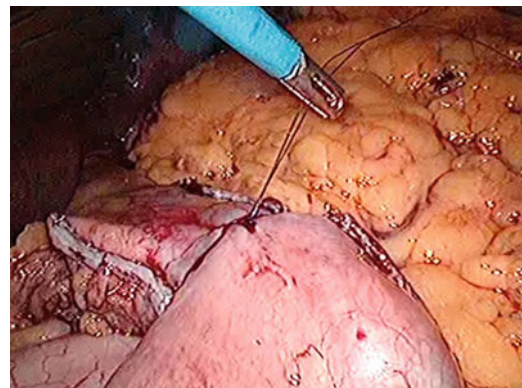


Fig. 12 Additional reinforcement stitch at the level of the gastrojejunostomy

and pulling the omentum to the right exposes the Petersen's space (Fig. 13b). For closure of the defects with a V-lock™, the same exposure is used. An exception is made in elderly: if there is too much traction on the gastro-enterostomy, the defects are left open.

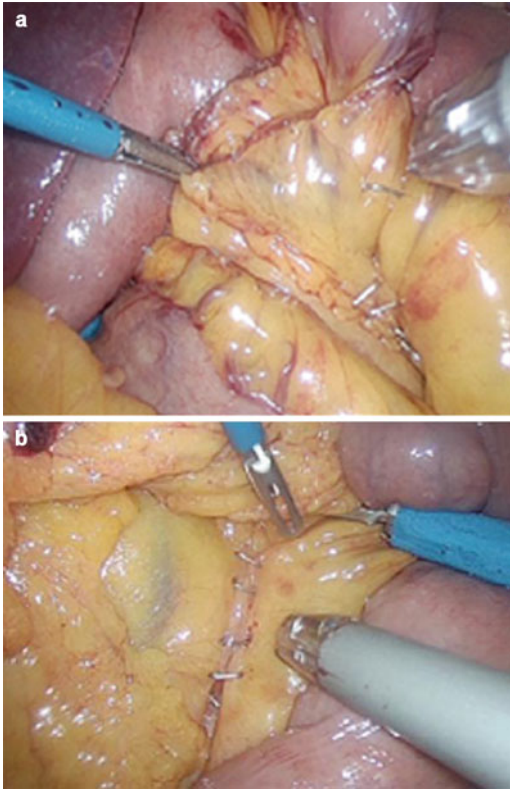


Fig. 13 Closure of the mesenteric gaps with stapler. (a) Mesenteric gap at the entero-enterostomy. (b) Petersen's space

24.3.8 Completion

To prevent postoperative bleeding, all staple lines are inspected at an elevated systolic arterial pressure above 130 mmHg [13] and any detected bleeding points are clipped. The entero-enterostomy is buried underneath the omentum, and the left lateral trocar port site is closed with the help of the Endo Close™ trocar site closure device, in order to prevent lateral entrapment or hernia formation (Fig. 14). The left lateral incision is infiltrated with a long-acting local anesthetic and a drain is passed through the incision, so that it lies next to the gastric pouch. The drain is fixed cutaneously with a Polysorb stitch.

24.4 Advice for the Initial Cases

In order to get used to the LRYGB, it is advisable to choose patients without an extreme BMI, and with a female fat distribution (mainly extra-

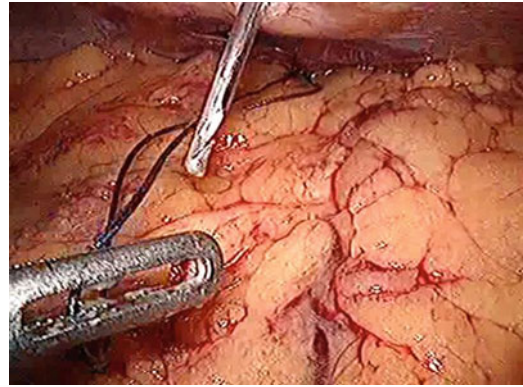


Fig. 14 Closure of the left lateral trocar port site with the Endo Close™ trocar site closure device

abdominal fat) for allowing a good learning curve for the initial cases. Patients should be prescribed a preoperative high protein diet for 14 days to reduce the size of the liver; a 5–10% reduction in weight should be achieved. It is preferable to seek highly experienced assistance even if it entails a delay for the operation. Preoperatively, after insufflation and appropriate (high enough) trocar placement, evaluate all important anatomical landmarks, including the angle of His. Surgery may be initiated by splitting the omentum and identifying the ligament of Treitz. Pull up the small bowel, evaluate the mesenteric length, and check if an antecolic gastroenterostomy can be safely constructed without traction. By using the stepwise approach as described earlier, a safe Roux-en-Y gastric bypass can be performed successfully, with favorable outcomes.

24.5 Postoperative Care

On the first postoperative day, oral intake is resumed, and the drain and any intravenous infusions are removed. Upper gastrointestinal imaging is not routinely performed. Generally, patients are discharged on the first postoperative day with specific dietary instructions. To prevent deep venous thrombosis, patients receive a daily subcutaneous injection with low-molecular-weight heparin for 10 days. In addition, a proton pump inhibitor (omeprazole 20 mg) is prescribed for 3 months to prevent marginal ulcer formation. A double dose is

prescribed in patients who smoke or patients on anticoagulants or non-steroidal anti-inflammatory drugs. The first follow-up visit is scheduled at 6 weeks postoperatively. Thereafter, patients visit at 6, 12, and 24 months postoperatively.

24.6 Conclusion

The LRYGB is a safe and easily reproducible surgical weight-loss procedure. Maximum standardization of the operation and high surgical volumes contribute to low 30-day morbidity and mortality rates.

24.7 Key Learning Points

The Standardized Laparoscopic Roux-en-Y Gastric Bypass Technique:

- Is reproducible, fast, and safe
- Is associated with minimal morbidity and mortality
- Can be used in complex revisional bariatric surgery

References

1. Dillemans B, Sakran N, Van Cauwenberge S, Sablon T, Defoort B, Van Dessel E, et al. Standardization of the fully stapled laparoscopic Roux-en-Y gastric bypass for obesity reduces early immediate postoperative morbidity and mortality: a single center study on 2606 patients. *Obes Surg.* 2009;19(10):1355–64.
2. Agrawal S. Impact of bariatric fellowship training on perioperative outcomes for laparoscopic Roux-en-Y gastric bypass in the first year as consultant surgeon. *Obes Surg.* 2011;21(12):1817–21.
3. Vasas P, Dillemans B, Van Cauwenberge S, De Visschere M, Vercauteren C. Short- and long-term outcomes of vertical banded gastroplasty converted to Roux-en-Y gastric bypass. *Obes Surg.* 2013;23(2):241–8.
4. Khewater T, Yercovich N, Grymonprez E, Debergh I, Dillemans B. Conversion of both versions of vertical banded gastroplasty to laparoscopic Roux-en-Y gastric bypass: analysis of short-term outcomes. *Obes Surg.* 2019;29(6):1797–804.
5. Khewater T, Yercovich N, Grymonprez E, Horevoets J, Mulier JP, Dillemans B. Twelve-year experience with Roux-en-Y gastric bypass as a conversational procedure for vertical banded gastroplasty: are we on the right track? *Obes Surg.* 2019;29(11):3527–35.
6. Debergh I, Defoort B, De Visschere M, Flahou S, Van Cauwenberge S, Mulier JP, Dillemans B. A one-step conversion from gastric banding to laparoscopic Roux-en-Y gastric bypass is as safe as a two-step conversion: a comparative analysis of 885 patients. *Acta Chir Belg.* 2016;116(5):271–7.
7. Mulier JP, Dillemans B, Van Cauwenberge S. Impact of the patient's body position on the intraabdominal workspace during laparoscopic surgery. *Surg Endosc.* 2010;24(6):1398–402.
8. Lemmens L. Banded gastric bypass: better long-term results? A cohort study with minimum 5-year follow-up. *Obes Surg.* 2017;27(4):864–72.
9. Nergaard BJ, Leifsson BG, Hedenbro J, Gislason H. Gastric bypass with long alimentary limb or long pancreato-biliary limb – long-term results on weight loss, resolution of co-morbidities and metabolic parameters. *Obes Surg.* 2014;24(10):1595–602.
10. Higa K, Boone K, Arteaga González I, López-Tomassetti FE. Mesenteric closure in laparoscopic gastric bypass: surgical technique and literature review. *Cir Esp.* 2007;82(2):77–88.
11. Cho M, Pinto D, Carrodegua L, Lascano C, Soto F, Whipple O, et al. Frequency and management of internal hernias after laparoscopic antecolic antegastric Roux-en-Y gastric bypass without division of the small bowel mesentery or closure of mesenteric defects: review of 1400 consecutive cases. *Surg Obes Relat Dis.* 2006;2(2):87–91.
12. Madan AK, Lo Menzo E, Dhawan N, Tichansky DS. Internal hernias and nonclosure of mesenteric defects during laparoscopic Roux-en-Y gastric bypass. *Obes Surg.* 2009;19(5):549–52.
13. Mulier J, Dillemans B, Vandrogenbroeck G, Akin F. The effect of systolic arterial blood pressure on bleeding of the gastric stapling during laparoscopic gastric bypass surgery. *Obes Surg.* 2007;17:A1051.